

# Five-year follow-up of a randomized, controlled trial comparing saphenofemoral ligation and stripping of the great saphenous vein with endovenous laser ablation (980 nm) using local tumescent anesthesia

Stefanie A. Gauw, CRC, James A. Lawson, MD, PhD, Clarissa J. van Vlijmen-van Keulen, MD, PhD, Pascal Pronk, MD, Menno T. W. Gaastra, MD, and Michael C. Mooij, MD, *Alkmaar, The Netherlands*

**Objective:** The objective of this study was to compare the long-term results (groin-related recurrence, great saphenous vein [GSV] occlusion rate, Clinical class, Etiology, Anatomy, and Pathophysiology [CEAP] staging, and quality of life [QoL]) after the treatment of a GSV incompetence by saphenofemoral ligation and stripping (SFL/S) with endovenous laser ablation bare fiber, 980 nm (EVLA).

**Methods:** Patients with GSV insufficiency and varicose veins were randomized to either undergo SFL/S or EVLA, both of which were performed under tumescent anesthesia. The long-term results, which included the anatomic occlusion rate, varicose vein recurrence at the saphenofemoral junction (SFJ), relief of venous symptoms and QoL, were compared up to 5 years after treatment.

**Results:** A total of 130 legs of 121 patients were treated with either SFL/S ( $n = 68$ ) or EVLA ( $n = 62$ ). In the first 12 months, three recanalizations of the GSV were observed after EVLA. Up to 5 years later, more recurrent varicose veins caused by neoreflux in incompetent tributaries of the SFJ were observed in after EVLA (31%; 19/61) compared with SFL/S (7%; 4/60;  $P < .01$ ). Neovascularization in the groin with clinically visible recurrence identified at 3 and 5 years post-treatment follow-up was only observed in the SFL/S group ( $n = 6$ ). After 5 years, clinically visible recurrences originating from the SFJ region after EVLA were observed 33% (20/61) compared with 17% of patients (10/60) after SFL/S ( $P < .04$ ). In both treatment groups, venous symptoms improved significantly. Patients in both groups reported a continuing significant cosmetic improvement measured on a visual analog scale of 1 to 10 (mean, 7.49;  $P < .01$ ). There was no difference in the CEAP staging and a standardized, non-disease-specific instrument for describing and valuing health states (EuroQol-5D), between the groups up to 5 years after follow-up.

**Conclusions:** At the 5-year follow-up, a significantly higher varicose vein recurrence rate originated at the SFJ region after EVLA compared with SFL/S. There were no differences in the relief of venous symptoms, CEAP staging, or general QoL between the groups. (*J Vasc Surg* 2016;63:420-8.)

Over the last 15 years, several minimally invasive techniques have been developed to treat saphenous vein incompetence. Ongoing innovations have also improved efficacy and patient comfort.<sup>1,2</sup> Currently, conventional open varicose vein surgery, such as high ligation and stripping of the saphenous vein, is replaced by endovenous ablation as the treatment of first choice, following the recommendations

of the guidelines in the field of venous disease.<sup>3</sup> A recent, well-designed systematic review evaluating endovenous ablation and open surgical interventions found that primary failure and recurrence in endovenous laser ablation (EVLA) and radiofrequency ablation (RFA) were nonsignificantly different compared with surgery. However, it was suggested that the incidence of reflux in tributaries and neovascularization might differ between the procedures with and without saphenofemoral ligation (ie, more reflux may occur in the tributaries in the procedures without saphenofemoral ligation, and more neovascularization may follow saphenofemoral ligation), which may influence the long-term effectiveness of endovenous techniques and surgery in addition to primary failure.<sup>1</sup> Therefore, the long-term results of our randomized trial comparing both techniques were evaluated to answer this question. Our primary objective was to detect varicose vein recurrence in the groin area, which might influence quality of life (QoL) and Clinical class, Etiology, Anatomy, and Pathophysiology (CEAP) staging. Recurrent varicose veins at other locations were not systematically recorded because they could also be the result of disease progression outside the treated area.

From the Centrum Oosterwal.

Author conflict of interest: none.

This study was presented in the scientific program at the 2014 Annual Meeting of the Deutsche Gesellschaft für Phlebologie in Munich, Germany, September 16-20, 2014.

Correspondence: Stefanie A. Gauw, CRC, Centrum Oosterwal, Comeniusstraat 3, 1817 MS Alkmaar, The Netherlands (e-mail: [s.gauw@centrum-oosterwal.nl](mailto:s.gauw@centrum-oosterwal.nl); [s.a.gauw@casema.nl](mailto:s.a.gauw@casema.nl)).

The editors and reviewers of this article have no relevant financial relationships to disclose per the JVS policy that requires reviewers to decline review of any manuscript for which they may have a conflict of interest.

0741-5214

Copyright © 2016 by the Society for Vascular Surgery. Published by Elsevier Inc.

<http://dx.doi.org/10.1016/j.jvs.2015.08.084>

Duplex ultrasonography (DUS) confirmed and clinically established recurrence, complementary treatments, relief of venous symptoms, QoL, and CEAP were evaluated during a 5-year follow-up period. The short-term results, including postoperative pain, time to recovery, QoL, and complications were described in our previous publication.<sup>4</sup> From this 1-year follow-up study, it was concluded that patients treated with EVLA experienced significantly more postoperative pain, resulting in more restricted mobility and less self-care and daily activities compared with patients who underwent saphenofemoral ligation and stripping (SFL/S) during the first 2 postoperative weeks.

## METHODS

This study was designed as a controlled, single-center, prospective, randomized, nonblinded trial carried out in a high-volume outpatient clinic specializing in venous disease. Approval was obtained from the regional medical ethics committee. The main outcome measurement is the percentage of recurrence of reflux at the saphenofemoral junction (SFJ) observed after a post-treatment follow-up of 10 years. This article describes the follow-up results after 5 years. Secondary outcome measurements include the general EuroQoL-5D questionnaire, relief of venous symptoms, postoperative complications, CEAP stage, and patient satisfaction.

### Patients

All patients were referred by a general practitioner for the diagnosis and treatment of primary varicose veins. An experienced phlebologist recorded their medical histories and performed physical examinations, which included lower limb DUS (Biosound Esaote MyLab 25; Europe BV, Maastricht, The Netherlands). DUS was performed in an upright position, using manual compression and release of the calf and the Valsalva maneuver to visualize the flow and reflux. Both procedures are performed at screening for every patient. Incompetence of the great saphenous vein (GSV) was defined as a reflux less than 0.5 seconds after calf compression and release or after the Valsalva maneuver. The inclusion criteria were a length of the incompetent GSV of at least 15 cm measured from the SFJ downward, with a diameter of greater than 3 mm and less than 1.5 cm. The exclusion criteria were having a previous surgical treatment or an intrafascial GSV length of less than 15 cm, pregnancy, and immobility. If patients were eligible for surgery, agreed to undergo the procedure under local tumescent anesthesia, and met the inclusion criteria, they were invited to participate in the study. Patients were asked for willingness to be monitored for a follow-up period of 10 years. A yearly visit was scheduled within a time window of 3 months. After written informed consent was obtained, computer randomization (1:1) was performed to assign participants to either the SFL/S or the EVLA procedure. All collected data were evaluated in accordance with the Declaration of Helsinki. Patients with bilateral GSV incompetence were randomized only once.

After the initial visits, including surgical or endovenous treatment, the long-term data of this ongoing study were

collected within 6 months post-treatment, followed by yearly visits for up to 5 years. During the follow-up visits, a phlebologist performed a physical examination and DUS. Recanalizations of the treated GSV segment and recurrent varicose veins were documented. DUS was performed in an upright position and only groin-related recurrences were documented. After SFL/S, a varicose vein recurrence, observed on DUS, was defined as a new refluxing vein in the GSV area with a diameter of 3 mm or greater, originating from the groin and connected through neovascularization with the residual stump of the GSV or the femoral vein, and with a reflux of less than 0.5 seconds. A clinically visible refluxing vein with a diameter of less than 3 mm was also considered as a recurrence. After EVLA, a recurrence detected on DUS was defined as the ability to compress the GSV ( $\geq 10$ -cm length), or as a reflux of less than 0.5 seconds in a tributary vein originating from the groin and connected with the residual stump of the GSV or femoral vein. New reflux, or perhaps better described as neoreflux, usually appear in preexisting veins in the postoperative period.<sup>5</sup> We categorized duplex recurrence only as not clinically visible, or when legs do not have visible varicose veins around that area. A clinically diagnosed recurrence was defined as being visible on DUS and clinically visible varicose veins.

The presence of clinically visible recurring varicose veins, edema, and cutaneous changes were staged using the CEAP classification. Other documented outcomes were long-term post-treatment complications such as paresthesia and hyperpigmentation. Residual or new symptoms of chronic venous disease, cosmetic judgment by the patient in a visual analog scale and QoL measurements using the EuroQoL-5D questionnaire were recorded. These long-term results were compared between both groups and with the condition before treatment.

### Procedures

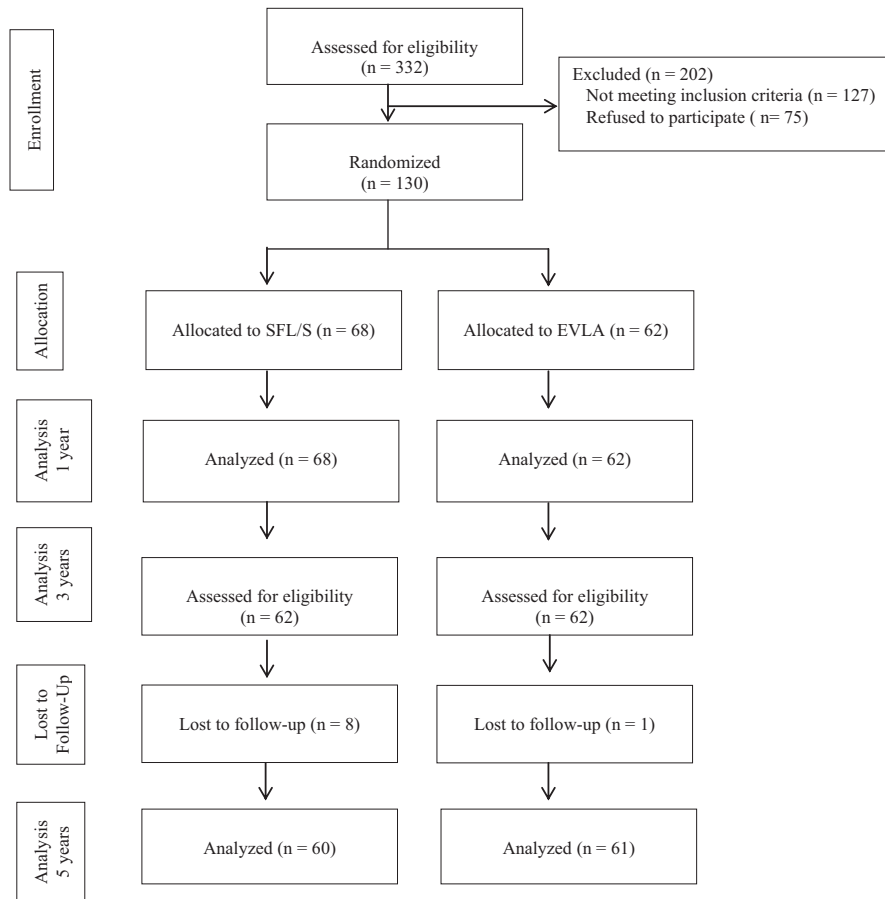
All treatments were performed under tumescent anesthesia and preoperative and perioperative DUS guidance.

**SFL/S.** After local anesthesia, a groin incision was made and high ligation and division of the GSV (flush at the SFJ) was performed. All groin-related tributaries that originate from the SFJ were divided and ligated, followed by inversion stripping (Multistrip Prodimed S.A.S.) of the GSV.

**EVLA.** DUS-guided percutaneous access to the GSV around the knee was obtained. After introducing the bare fiber, the tip was positioned approximately 1.5 to 2 cm below the SFJ. After tumescent anesthesia, a 980-nm diode laser equipment (Biolitec) was used to ablate the GSV with 12 W of continuous wave laser energy. More detailed information is described in a previous publication.<sup>4</sup>

### Sample size and statistical methods

Sample size calculations were based on detecting a 10% difference in recurrent varicose veins on DUS imaging between the treatment groups. Assuming an  $\alpha$  (type I error) of .05 and  $\beta$  (type II error) of .20, 137 patients were required in each group. Analyses were performed using SPSS version 18 (SPSS, Inc, Chicago, Ill). Nominal variables were tested



**Fig 1.** Consort diagram. Trial recruitment, randomization, treatment allocation and follow-up, in terms of legs. *EVLA*, Endovenous laser ablation; *SFL/S*, saphenofemoral ligation and stripping.

by the  $\chi^2$  test. For group comparisons of ordinal variables, the Mann-Whitney *U* test was used. Continuous variables were compared using the *t*-test or the Mann-Whitney test, depending on normality of the distribution of the variables. Normality was tested using the Kolmogorov-Smirnov test.  $P < .05$  was considered significant. DUS confirmed reflux, clinical recurrence and the need for secondary procedures were analyzed by Kaplan-Meier statistics (the log-rank test). The study design included a yearly interim analysis.

## RESULTS

Between June 2007 and December 2008, 312 patients (333 legs) were invited to participate in the study. One-hundred thirty legs of 121 patients with GSV insufficiency were randomized to undergo SFL/S ( $n = 68$ ) or EVLA ( $n = 62$ ; Fig 1). The groups had homogenous demographic characteristics, CEAP classification and symptoms of chronic venous disease at the time of randomization (Table I). After 5 years, nine patients were lost to follow-up (eight SFL/S patients and one EVLA patient). The reasons for the higher lost to follow-up rate in the SFL/S group included

emigration ( $n = 1$ ), pregnancy ( $n = 1$ ), false inclusion ( $n = 1$ ), inability to visit the hospital ( $n = 2$ ), and unknown reasons ( $n = 3$ ). The patient lost to follow-up in the EVLA group emigrated.

### Primary outcome

At the 5-year follow-up visit in the SFL/S group, ten patients in the SFL/S group had experienced varicose vein recurrence, five (four clinically evident) within the first 2 years owing to neoreflux at the SFJ or anterior accessory saphenous vein (AASV), and the remaining six after 2 years owing mainly to neovascularization. By the 5-year mark in the EVLA group, 25 had developed neoreflux at the SFJ into the AASV and had clinically visible veins. Three instances of recanalization were already detected in the GSV within the first 6 months, of which one was clinically visible. Recurrence was clinically evident in 20 of the 25 cases of reflux detected by ultrasound after 5 years (Table II).

Freedom from total clinical recurrence and total ultrasound-detected recurrence in the groin are shown in Figs 2 and 3, respectively. Over the 5-year period, clinical

**Table I.** Patient characteristics of study population and Clinical class, Etiology, Anatomy and Pathophysiology (CEAP) classification

Variable	SFL/S (n = 68)	EVLA (n = 62)	$\chi^2$ test, P value
Male/female, No.	15/53	16/46	.62
Left/right leg, No.	27/41	27/35	.66
Age, mean (SD)	50 (10.5)	49 (11.0)	.68 <sup>a</sup>
BMI, mean (SD)	24.5 (3.7)	25 (3.3)	.57 <sup>a</sup>
Diameter of SFJ, cm mean (SD)	0.92 (0.27)	0.88 (0.22)	.43 <sup>a</sup>
Diameter GSV, cm mean (SD) (at knee level)	0.64 (0.14)	0.64 (0.16)	.90 <sup>a</sup>
Length of treated GSV, cm mean (SD)	40.8 (7.5)	—	—
Total joules, mean (SD)	—	2600 (428)	—
Joules/cm, mean (SD)	—	64.5 (6.8)	—
CEAP classification			
C2, No. (%)	26 (38)	29 (47)	.29
C3, No. (%)	36 (53)	29 (47)	.43
C4, No. (%)	5 (7)	4 (6)	.86
C5, No. (%)	1 (1)	0 (0)	.34

BMI, Body mass index; EVLA, endovenous laser ablation; GSV, great saphenous vein; SD, standard deviation; SFJ, saphenofemoral junction; SFL/S, saphenofemoral ligation and stripping.

<sup>a</sup>t-test.

Source: Pronk P, et al. Eur J Vasc Endovasc Surg 2010;40:649-56.

**Table II.** Duplex recurrence only and clinically visible recurrence up to 5 years

	DUS recurrence only		Clinically visible		Total		P value
	SFL/S	EVLA	SFL/S	EVLA	SFL/S	EVLA	$\chi^2$
AASV	1	6	4	19	5	25	<.01
Neovascularization	2	5	6	0	8	5	.36
Recanalization GSV	0	2	0	1	0	3	—

AASV, Anterior accessory saphenous vein; DUS, duplex ultrasonography; EVLA, endovenous laser ablation; GSV, great saphenous vein; SFL/S, saphenofemoral ligation and stripping.

recurrence in the groin occurred in 17% of the SFL/S patients and 33% of the EVLA patients (log-rank test  $P = .04$ ). The incidence of recurrence detected by DUS at 5 years was 49% after the EVLA procedure vs 23% after the SFL/S procedure (log-rank test  $P = .02$ ).

### Secondary outcomes

**Clinical outcomes.** Compared with the preoperative values, CEAP classification had improved after 1 year and the improvement was maintained for up to 5 years for all patients, with no difference between the groups at any time point (Fig 4).

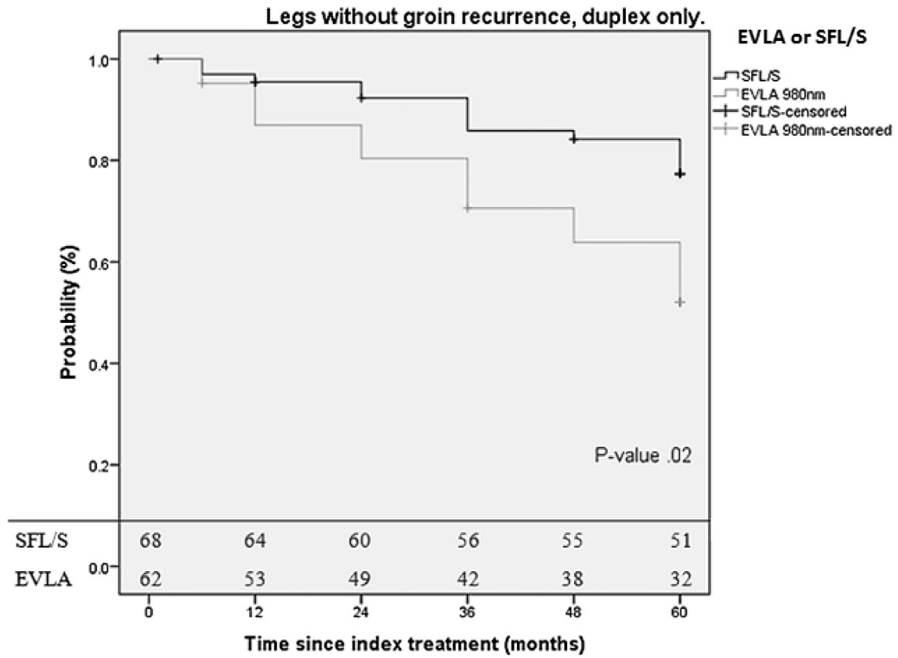
**Venous symptoms.** Both groups had significant improvements in varicose vein-related symptoms compared with the preoperative state ( $P < .01$ ), which was comparable between groups (Table III). Varicose vein-related symptoms before treatment were significantly reduced after 1 year and continued to improve for up to 5 years in both groups. Patients in both groups reported significant continuing cosmetic improvement measured on a visual analog scale of 1 to 10 (mean, 7.5;  $P < .01$ ) without any difference between the SFL/S and EVLA groups ( $P = .048$ ; Fig 5).

### General QoL

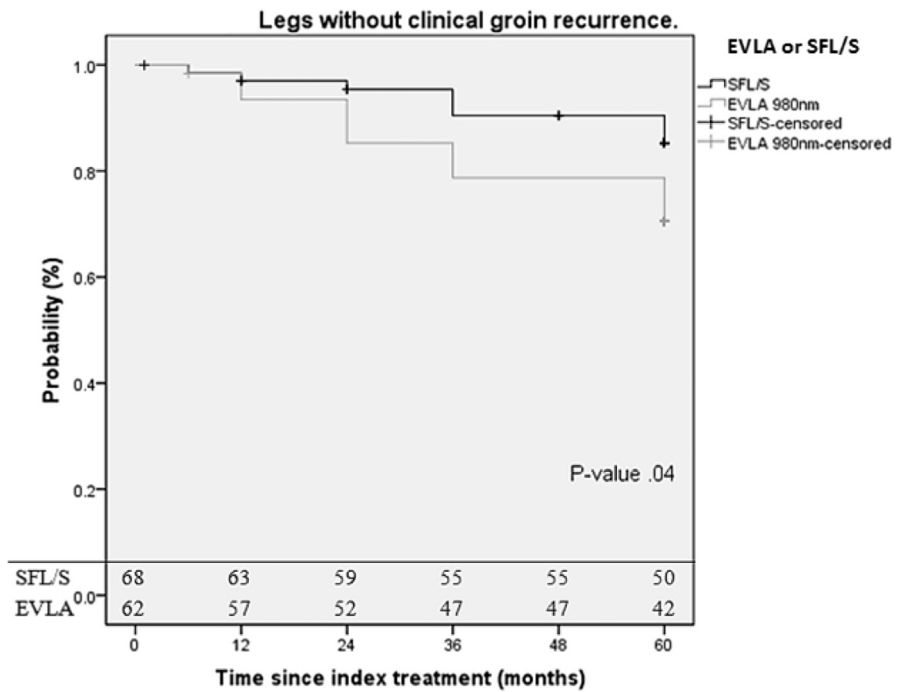
No impairment or improvement in patient QoL was measured in the five dimensions of the EuroQOL-5D at 6 months or 5 years after either SFL/S or EVLA.

### Secondary procedures

Treatment of the recurrent groin veins included high ligation, endovenous thermal ablation, or foam sclerotherapy. In the SFL/S group, foam sclerotherapy was used to treat 4 out of 10 (7%) patients with new refluxing veins. In contrast, in the EVLA group, foam sclerotherapy was used in nine patients (15%). In three patients, endovenous thermal ablation was successful for the closure of the incompetent AASV (two VNUS ClosureFAST and one EVLA Radial 1470 nm). In one patient with an incompetent AASV, surgical high ligation was needed because of the short length and the primarily subcutaneous positioning of the involved vein segment. To occlude a symptomatic recanalized GSV, a second thermal ablation (VNUS ClosureFAST) was attempted but was not successful. Two other recanalizations of the GSV were not treated because of the absence of venous symptoms. The freedom rate from secondary procedures for groin recurrence



**Fig 2.** Kaplan-Meier curves for freedom from groin recurrence observed by duplex ultrasound only. *EVLA*, Endovenous laser ablation; *SFL/S*, saphenofemoral ligation and stripping.



**Fig 3.** Kaplan-Meier curves for freedom from clinical groin recurrence. *EVLA*, Endovenous laser ablation; *SFL/S*, saphenofemoral ligation and stripping.

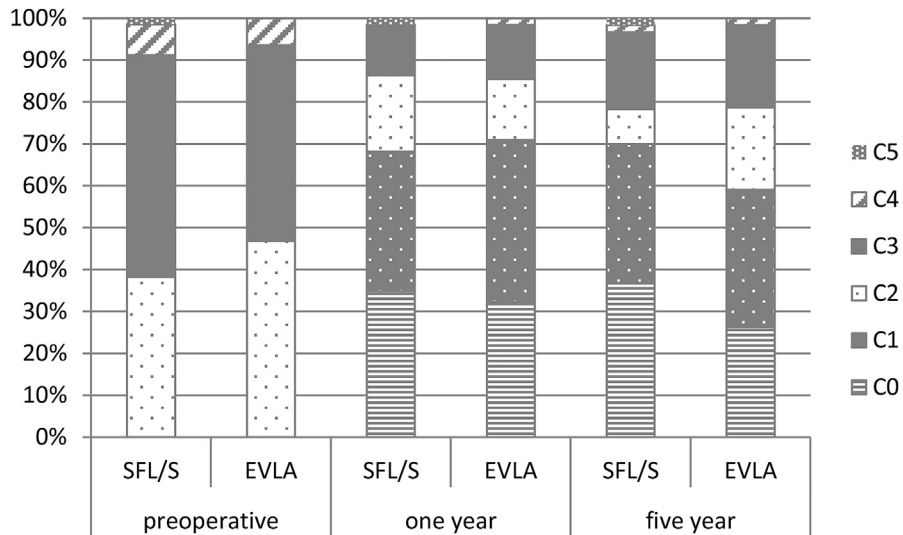


Fig 4. Clinical class, Etiology, Anatomy and Pathophysiology (CEAP) classification in all patients. No difference between the groups. EVLA, Endovenous laser ablation; SFL/S, saphenofemoral ligation and stripping.

Table III. Vein-related symptoms and signs over 5 years in both groups

	Baseline, No. (%)		1 Year, No. (%)		5 Years, No. (%)	
	SFL/S (n = 68)	EVLA (n = 62)	SFL/S (n = 66)	EVLA (n = 62)	SFL/(n = 60)	EVLA (n = 61)
Tired legs	35 (52)	31 (50)	8 (12)	5 (8)	1 (2)	1 (2)
Edema	32 (47)	21 (34)	10 (15)	6 (10)	6 (10)	6 (10)
Itching	26 (38)	20 (32)	6 (9)	3 (5)	1 (1)	3 (5)
Cosmetic	13 (19)	13 (20)	10 (15)	5 (8)	3 (5)	8 (13)
Pain	13 (19)	9 (15)	6 (9)	1 (2)	1 (1)	4 (7)
Restless legs	6 (9)	11 (18)	4 (6)	10 (16)	0	4 (7)
Cramps	8 (12)	8 (13)	2 (3)	5 (8)	2 (3)	7 (11)
Other	7 (10)	9 (15)	0	0	1 (2)	2 (3)
Persisting neurosensory deficit			1 (2)	0	1 (2)	0
No complaints	1 (1)	3 (5)	38 (53)	35 (57)	45 (75)	38 (62)

EVLA, Endovenous laser ablation (980 nm); SFL/S, saphenofemoral ligation and stripping. No significant differences between the SFL/S and EVLA group.

varicose veins is shown in Fig 6. After 5 years of follow-up, 80% of patients in the SFL/S group did not undergo a secondary procedure compared with 70% of patients in the EVLA group (log-rank test,  $P = .20$ ).

**Late complications**

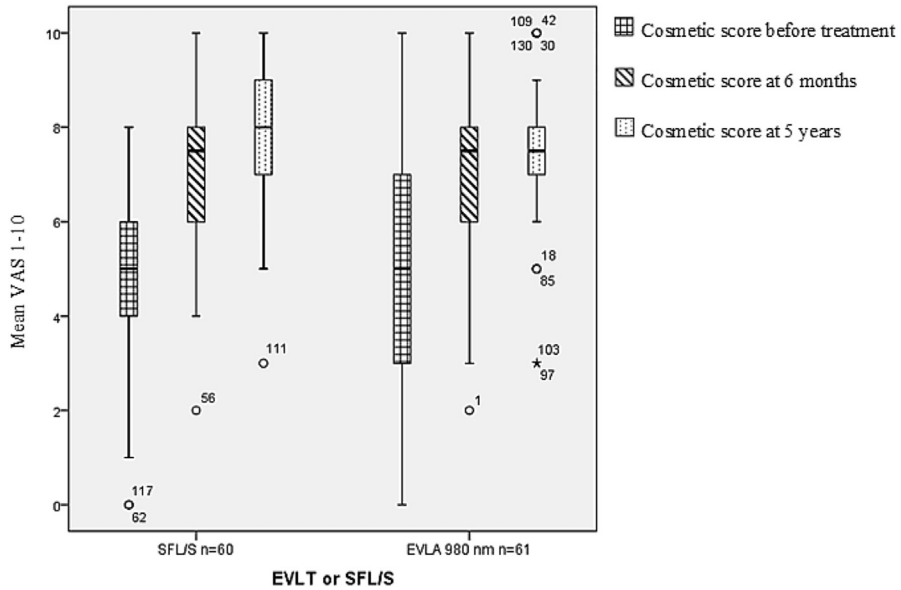
There was one late complication noted, specifically, a pretibial neurosensory deficit that persisted for 5 years after SFL/S. The patient did not think that this complication hindered their activities of daily living.

**DISCUSSION**

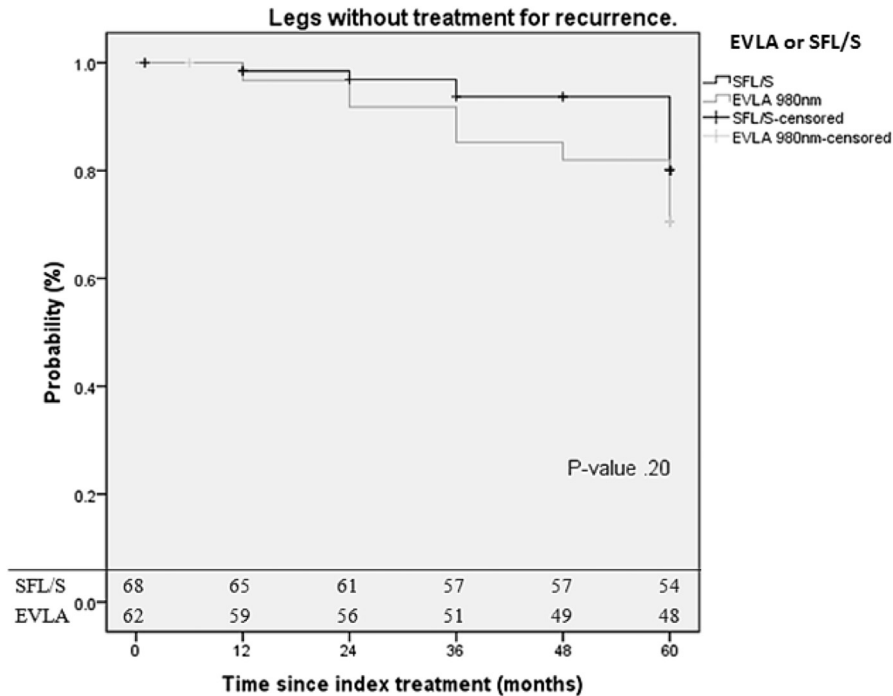
The 5-year results of our randomized clinical study comparing two venous procedures performed under local tumescent anesthesia demonstrate that after 5 years no failures of long-term occlusion from the GSV had occurred after SFL/S, whereas failures after EVLA were observed

in a few cases. Anatomic failure after stripping is often observed in randomized, controlled trial where SFL/S is performed using general anesthesia and is not always conducted by fully trained staff surgeons.<sup>6-9</sup> Rasmussen et al<sup>10</sup> suggested that, in specialized centers, only highly experienced surgeons focused on varicose vein disease perform the open surgery, which may improve its benefits. We hypothesized that performing open surgery under DUS guidance and using local anesthesia could also improve the success rate.<sup>10,11</sup> In our study, none of the patients had a residual stump after SFL/S and all of the site branches were ligated when performing a crosssectomy. Open surgery performed under local tumescent anesthesia allows for gentle tissue separating and more bloodless preparation, which minimize the risk of surgical trauma.

However, the number of legs with DUS detected and clinical recurrences from the groin area in our study after



**Fig 5.** Cosmetic results (visual analog scale [VAS] 1-10) before saphenofemoral ligation and stripping (SFL/S) and endovenous laser ablation (EVLA), and at 6 months and 5 years follow-up. Preoperative median VAS in both groups (interquartile range [IQR], 2 for SFL/S; IQR, 4 for EVLA). After 6 months and 5 years median VAS was >7 (IQR, 2). At 5-year follow-up for EVLA, the IQR was 1.



**Fig 6.** Kaplan-Meier curves for freedom from treatment of clinical groin recurrence. EVLA, Endovenous laser ablation; SFL/S, saphenofemoral ligation and stripping.

5 years was significantly higher in the EVLA group than after surgery. After 1 year of follow-up, this difference was not so prominent.<sup>4</sup> This finding is in agreement with

several previous publications of similar randomized long-term studies showing a higher rate of neoreflux in SFJ tributaries after EVLA.<sup>10-13</sup>

To diminish the prevalence of SFJ recurrence after endovenous ablation caused by incompetent accessory veins, avoiding residual GSV stump formation is recommended, analogous to open surgery.<sup>14</sup> In most cases, if present, the AASV drain in the GSV is close to the SFJ.<sup>15</sup> There is no consensus regarding the placement of the laser fiber tip (or RF catheter) toward the SFJ. Bare tip endovenous laser catheters and ClosureFAST RFA catheters both have an associated forward thrust of heat. For this reason, some authors advise keeping a distance of approximately 2 cm from the confluence to prevent intimal damage at the SFJ, which can provoke a heat-induced thrombus or deep venous thrombosis.<sup>16</sup> In accordance with our study protocol, the distance from the SFJ was kept between 1.5 and 2 cm. Our previous publication on 1-year post-treatment results reported that heat-induced thrombus at the SFJ was observed on DUS in 3 patients (5%) 1 week after EVLA. In all cases, the thrombus dissolved without treatment and could not be detected on DUS at 6 weeks follow-up. No major complications, such as deep venous thrombosis and wound infection, were encountered.<sup>2</sup> To prevent the recurrence of SFJ tributaries, especially the AASV, it might be necessary to ablate the GSV up to and including the SFJ. It is suggested that, with the use of a radial laser fiber without a forward laser beam, it is possible to safely occlude the saphenous vein completely to the junction.<sup>17</sup> Further data are needed to prove that this technique will prevent neoreflux in groin-related tributaries that originate from the SFJ without provoking long-term neovascularization. A randomized, controlled trial to be performed in our center that will investigate the usefulness of this technique in preventing neoreflux is in a preparatory phase.

In our previous publication that covered the 1-year results, we concluded that conventional surgery by SFL/S and EVLA, both performed under local tumescent anesthesia, were well-tolerated, with no differences between their complication rates, short-term cosmetic results, CEAP classifications, and recurrence rates. However, in the post-treatment QoL assessment in the second week, patients in the EVLA group experienced significantly more pain, resulting in a restriction of mobility, self-care, and daily activities compared with patients who underwent SFL/S.

Six years ago, we decided to stop using bare fibers and switched to VNUS ClosureFAST or a Radial fiber laser procedure as a first choice for treating GSV reflux. Several published randomized, controlled trials that compared the use of bare tip fibers and these new modalities showed better postoperative recovery and faster return to work using RFA or endovenous laser treatments with a modified laser tip.<sup>18,19</sup> We started a trial comparing the benefits and safety of VNUS ClosureFAST to a Radial fiber. The 3-year results are forthcoming.

The results of the secondary outcomes concerning symptom relief, cosmetic scores, CEAP staging, and QoL at 5 year after SFL/S and EVLA were favorable. These favorable results are comparable between groups and persisted for up to 5 years.

Our study has some limitations that were also discussed in our previous publication. Varicose signs are described and staged by the CEAP classification. We did not assess the severity of disease using the VCSS classification, which would be complementary and is designed for evaluations of the effectiveness of therapy in severe chronic venous disease over time.<sup>20</sup> The suggestion of more serious post-treatment pain in the EVLA group was confirmed in the initial 1-year interim analysis. The significantly higher rate of post-treatment pain after EVLA was considered to be of clinical relevance, and we decided to stop further enrollment before the calculated sample size was reached.<sup>4</sup>

The major strength of this study is that, for a long-term follow-up study, there is only a small number of dropouts (7%), which gives us a relevantly high number of participants/legs that were followed up annually for 5 years. In similar 5-year follow-up studies, not all patients are evaluated at the 5-year visit.<sup>10,12</sup> The 5-year results in those studies were estimated by Kaplan-Meier analyses and log-rank tests. We will follow our patients for a total of 10 years because neovascularization after SFL/S can still occur even 7 to 10 years after the procedure.<sup>14</sup>

Before the start of the study, we decided to investigate explicitly groin recurrence because high ligation was not performed during EVLA. We hypothesized that studying recurrence at other locations would yield equivalent results. However, some authors found more recurrence after SFL/S at other locations compared with EVLA.<sup>11</sup>

## CONCLUSIONS

We found that EVLA with a 980 nm wavelength and a bare tip fiber has no advantage over high ligation of the SFJ and stripping under tumescent anesthesia for the treatment of GSV reflux for up to 5 years. Compared with the 1-year follow-up, after 5 years there is a significantly higher recurrence rate, mainly caused by neoreflux from the SFJ in the AASV after EVLA in comparison with the SFL/S procedure. Both procedures are safe, with the same symptomatic improvement even after 5 years. However, the postoperative recovery after both studied procedures is much worse compared with recent endovenous treatment modalities. That is why RFA or EVLA with a modified laser tip is our current treatment of choice. SFL/S under tumescent anesthesia is a good alternative if endovenous treatment is unsuitable.

The authors gratefully acknowledge the support of T. J. van der Ploeg, who assisted in the statistical analysis for this study, Professor J. A. Rauwerda, MD, PhD, who provided recommendations regarding the set-up of the study, and A. R. van Goethem, one of the surgeons who performed SFL/S and EVLA procedures and is coauthor of our first article.

## AUTHOR CONTRIBUTIONS

Conception and design: SA, JA, CJ  
Analysis and interpretation: SA, JA, CJ  
Data collection: SA, JA, CJ, PP, MG, MC  
Writing the article: SA, JA, CJ



Critical revision of the article: JA, CJ, MC

Final approval of the article: JA, CJ

Statistical analysis: SA, JA

Obtained funding: Not applicable

Overall responsibility: JA

## REFERENCES

1. Siribumrungwong B, Noorip P, Wilasrusmee C, Attia J, Thakkinstian A. A systematic review and meta-analysis of randomised controlled trials comparing endovenous ablation and surgical intervention in patients with varicose vein. *Eur J Vasc Endovasc Surg* 2012;44:214-23.
2. Lynch NP, Clarke M, Fulton GJ. Surgical management of great saphenous vein varicose veins: a meta-analysis. *Vascular* 2015;23:285-96.
3. Gloviczki P, Comerota AJ, Dalsing MC, Eklof BG, Gillespie DL, Gloviczki ML, et al. The care of patients with varicose veins and associated chronic venous diseases: clinical practice guidelines of the society for vascular surgery and the American Venous Forum. *J Vasc Surg* 2011;53(5 Suppl):2S-48S.
4. Pronk P, Gauw SA, Mooij MC, Gaastra MT, Lawson JA, van Goethem AR, et al. Randomised controlled trial comparing saphenofemoral ligation and stripping of the great saphenous vein with endovenous laser ablation (980 nm) using local tumescent anaesthesia: one year results. *Eur J Vasc Endovasc Surg* 2010;40:649-56.
5. Turton EP, Scott DJ, Richards SP, Weston MJ, Berridge DC, Kent PJ, et al. Duplex-derived evidence of reflux after varicose vein surgery: neoreflux or neovascularisation? *Eur J Vasc Endovasc Surg* 1999;17:230-3.
6. Carradice D, Mekako AI, Mazari FA, Samuel N, Hatfield J, Chetter IC. Randomized clinical trial of endovenous laser ablation compared with conventional surgery for great saphenous varicose veins. *Br J Surg* 2011;98:501-10.
7. Darwood RJ, Theivacumar N, Dellagrammaticas D, Mavor AI, Gough MJ. Randomized clinical trial comparing endovenous laser ablation with surgery for the treatment of primary great saphenous varicose veins. *Br J Surg* 2008;95:294-301.
8. Subramonia S, Lees T. Radiofrequency ablation vs conventional surgery for varicose veins - a comparison of treatment costs in a randomised trial. *Eur J Vasc Endovasc Surg* 2010;39:104-11.
9. Brittenden J, Cotton SC, Elders A, Ramsay CR, Norrie J, Burr J, et al. A randomized trial comparing treatments for varicose veins. *N Engl J Med* 2014;371:1218-27.
10. Rasmussen L, Lawaetz M, Bjoern L, Blemings A, Eklof B. Randomized clinical trial comparing endovenous laser ablation and stripping of the great saphenous vein with clinical and duplex outcome after 5 years. *J Vasc Surg* 2013;58:421-6.
11. Rass K, Frings N, Glowacki P, Hamsch C, Gräber S, Vogt T, et al. Comparable effectiveness of endovenous laser ablation and high ligation with stripping of the great saphenous vein: two-year results of a randomized clinical trial (RELACS study). *Arch Dermatol* 2012;148:49-58.
12. Disselhoff BC, der Kinderen DJ, Kelder JC, Moll FL. Five-year results of a randomized clinical trial comparing endovenous laser ablation with cryostripping for great saphenous varicose veins. *Br J Surg* 2011;98:1107-11.
13. Flessenkämper IH, Stenger D, Hartmann M, Hartmann K, Roll S. [Two-year results of a prospective randomised controlled multicenter trial to compare open operative therapy vs. Endoluminal venous laser therapy with and without high ligation for the therapy of varicose greater saphenous veins]. *Zentralbl Chir* 2015;140:27-34.
14. Geier B, Stücker M, Hummel T, Burger P, Frings N, Hartmann M, et al. Residual stumps associated with inguinal varicose vein recurrences: a multicenter study. *Eur J Vasc Endovasc Surg* 2008;36:207-10.
15. Mühlberger D, Morandini L, Brenner E. Venous valves and major superficial tributary veins near the saphenofemoral junction. *J Vasc Surg* 2009;49:1562-9.
16. Haqqani OP, Vasiliu C, O'Donnell TF, Iafrazi MD. Great saphenous vein patency and endovenous heat-induced thrombosis after endovenous thermal ablation with modified catheter tip positioning. *J Vasc Surg* 2011;54(6 Suppl):10S-7S.
17. Dragic P. "Laser crosssection", a State of Art in EVLA. Single center experience using radial fiber in more than 3000 EVLA performed. *Int Angiol* 2013;32(5 Suppl 1):104-5.
18. Doganci S, Demirkilic U. Comparison of 980 nm laser and bare-tip fibre with 1470 nm laser and radial fibre in the treatment of great saphenous vein varicosities: a prospective randomised clinical trial. *Eur J Vasc Endovasc Surg* 2010;40:254-9.
19. Shepherd AC, Gohel MS, Brown LC, Metcalfe MJ, Hamish M, Davies AH. Randomized clinical trial of VNUS closurefast radiofrequency ablation versus laser for varicose veins. *Br J Surg* 2010;97:810-8.
20. Vasquez MA, Rabe E, McLafferty RB, Shortell CK, Marston WA, Gillespie D, et al. Revision of the venous clinical severity score: venous outcomes consensus statement: special communication of the American Venous Forum Ad Hoc Outcomes Working Group. *J Vasc Surg* 2010;52:1387-9.

Submitted Feb 19, 2015; accepted Aug 17, 2015.